




Functional Neuroimaging as an Assessment Tool in Critically Ill Patients

Loretta Norton, PhD ^{1,2} Karnig Kazazian, BSc,¹ Teneille Gofton, MD,³
 Derek B. Debicki, MD, PhD,^{1,3} Davinia Fernandez-Espejo, PhD ^{4,5}
 Jonathan E. Peelle, PhD ⁶ Eyad Al Thenayan, MD,³ G. Bryan Young, MD,³ and
 Adrian M. Owen, PhD^{1,7}

Objective: Little is known about residual cognitive function in the earliest stages of serious brain injury. Functional neuroimaging has yielded valuable diagnostic and prognostic information in chronic disorders of consciousness, such as the vegetative state (also termed unresponsive wakefulness syndrome). The objective of the current study was to determine if functional neuroimaging could be efficacious in the assessment of cognitive function in acute disorders of consciousness, such as coma, where decisions about the withdrawal of life-sustaining therapies are often made.

Methods: A hierarchical functional magnetic resonance imaging (fMRI) approach assessed sound perception, speech perception, language comprehension, and covert command following in 17 critically ill patients admitted to the intensive care unit (ICU).

Results: Preserved auditory function was observed in 15 patients (88%), whereas 5 (29%) also had preserved higher-order language comprehension. Notably, one patient could willfully modulate his brain activity when instructed to do so, suggesting a level of covert conscious awareness that was entirely inconsistent with his clinical diagnosis at the time of the scan. Across patients, a positive relationship was also observed between fMRI responsivity and the level of functional recovery, such that patients with the greatest functional recovery had neural responses most similar to those observed in healthy control participants.

Interpretation: These results suggest that fMRI may provide important diagnostic and prognostic information beyond standard clinical assessment in acutely unresponsive patients, which may aid discussions surrounding the continuation or removal of life-sustaining therapies during the early post-injury period.

ANN NEUROL 2023;93:131–141

Neurologists are often asked to provide a prognosis for patients in the intensive care unit (ICU) with an acute disorder of consciousness. These estimations of the likelihood of functional recovery are a key factor in discussions surrounding the continuation, or withdrawal, of life-sustaining therapies. However, prognostication is typically very challenging as existing clinical tools focus on predicting a poor outcome (a clinical outcome no better than vegetative state [VS] or severe disability with total dependency).¹ When no indicators of a poor prognosis are

present, a patient is assumed to have an indeterminate outcome, as there are currently no accepted tools that are known to predict good functional recovery.²

Functional magnetic resonance imaging (fMRI), a neuroimaging technique used for measuring and mapping brain activity in response to external stimuli, is one tool that may be useful in this area. Most of the evidence relating to the prognostic potential of fMRI comes from research in chronic disorders of consciousness, such as the VS and minimally conscious state (MCS). Several studies have now shown that

View this article online at [wileyonlinelibrary.com](https://onlinelibrary.wiley.com/doi/10.1002/ana.26530). DOI: 10.1002/ana.26530

Received Apr 14, 2022, and in revised form Sep 29, 2022. Accepted for publication Oct 5, 2022.

Address correspondence to Dr. Norton, 266 Epworth Ave, London, Ontario N6A 2M3, Canada. E-mail: lnorton5@uwo.ca

From the ¹Brain and Mind Institute, Western University, London, Ontario, Canada; ²Department of Psychology, King's University College at Western University, London, Ontario, Canada; ³Department of Clinical Neurological Sciences, Schulich School of Medicine and Dentistry, Western University, London, Ontario, Canada; ⁴School of Psychology, University of Birmingham, Edgbaston, Birmingham, UK; ⁵Centre for Human Brain Health and School of Psychology, University of Birmingham, Edgbaston, Birmingham, UK; ⁶Center for Cognitive and Brain Health, Northeastern University, Boston, MA, USA; and ⁷Department of Physiology and Pharmacology and Department of Psychology, Schulich School of Medicine and Dentistry, Western University, London, Ontario, Canada

activation in response to external stimuli in higher-order integrative cortical areas is related to improvements in functional recovery in such patients.^{3–5} However, relatively few studies have examined whether fMRI can aid in prognostication in brain-injured patients in the ICU.^{6–11}

fMRI has also been used extensively to improve *diagnosis* in disorders of consciousness, but most studies have focused on patients who have transitioned from coma into the VS.¹² Misdiagnosis among this population is extremely high with upward of 40% initially diagnosed as VS reclassified as retaining some level of awareness when assessed by expert examiners.¹³ In one study, a motor imagery and a spatial navigation task were used to show that a patient in a VS could modulate the brain activity to command.¹⁴ The neural responses recorded were indistinguishable from those observed in healthy controls, providing the first evidence for intact command following in a behaviorally nonresponsive patient.¹⁵ Follow-up studies from several centers have shown that between 15% and 20% of patients clinically classified as VS are, in fact, able to perform such command-following tasks when assessed using an fMRI.¹⁶

In the current study, the same 2 fMRI mental imagery tasks that have been shown previously to reveal covert awareness in the VS were used to assess a group of brain-injured patients in the ICU.¹⁴ Because these tasks require patient cooperation in the form of “neural command following,” they allow consciousness to be inferred in a way that more passive sensory and perceptual tasks do not. Sound and language perception tasks were also administered to look for signs of lower-level cognition in the absence of covert awareness.^{14,17,18} We hypothesized that fMRI activity in response to this hierarchical set of tasks would be related to clinical outcome; that is to say, patients with activation similar to controls were predicted to have a more complete recovery from severe brain injury than those who showed no, or partial, fMRI activation.

Materials and Methods

Participants

A convenience sample of 17 critically brain-injured patients were recruited from the London Health Sciences Centre (LHSC; London, Ontario, Canada). Study enrollment was performed in a consecutive manner when both research staff and MRI equipment were available. Patient demographic data can be found in the Table . Patients were eligible for the study if they were 18 years of age or older, were admitted to the ICU following a severe brain injury of any etiology, were cardiovascularly stable and at low risk of deterioration during the procedure and transport to and from the MRI unit, had a low level of consciousness (Glasgow Coma Scale [GCS] ≤ 9) that was not related to administration of sedation, and had a normal hearing history based on a report from the patients’ families and no suspicion of injury to the hearing apparatus due to the cause of injury. Patients were ineligible for the study if they were hypothermic with a core

temperature below 35°C, had unstable cardiac or respiratory status as defined by irregular vital signs as determined by the attending intensivist that may have led to an adverse event during imaging, or had a contraindication for MRI. All patients were English speakers and all patients were mechanically ventilated at the time of imaging. Written informed consent was obtained from the substitute decision maker of each patient.

Fourteen right-handed healthy participants (23 ± 3 years, 9 men and 14 women) also took part in the study. All volunteers had no known neurological or psychiatric disease and provided their written informed consent. Ethical approval for the research study was obtained from the Health Sciences Research Ethics Board of Western University.

MRI Acquisition

Imaging was performed on three 1.5 T General Electric MRI systems at LHSC. Setup parameters were identical on all 3 scanners. The functional paradigms used a T2*-weighted acquisition sequence (TR = 2,500 ms, TE = 40 ms, matrix size = 64×64 , slice thickness = 3 mm, in-plane resolution = $3.75 \text{ mm} \times 3.75 \text{ mm}$, flip angle 90 degrees). We acquired 240 volumes for the auditory (sound and speech) paradigm and 134 volumes for each of the mental imagery paradigms. Each volume comprised 30 oblique interleaved slices. A T1-weighted axial spoiled gradient recalled (SPGR) pulse sequence with a 1 mm isotropic resolution was also obtained.

Stimuli

Auditory Paradigm. The hierarchical auditory paradigm was presented in an interleaved block design and consisted of 4 different auditory conditions: complex language, pseudoword sentences, signal correlated noise (SCN), and silence. Each condition was 30 seconds in length and repeated 5 times for a total of 10 minutes (4 conditions \times 30 seconds \times 5 repetitions).

The complex language condition involved 5 linguistically complex short stories designed to maximally drive language processing. This was accomplished using sentences that contained both subject-relative and object-relative embedded clauses within the narratives. This increased the complexity of the sentence structures, effectively making the stimuli more difficult to comprehend, and, subsequently, more effortful for the listener, as they increased the demands on syntactic processing.^{19,21}

In the pseudoword sentence condition, each word within the complex language condition was replaced with a pseudoword (a non-word that has no meaning in the English lexicon).²²

The complex language stimuli were also used to generate an unintelligible SCN²⁰ that had the same amplitude envelope and spectral profile as the complex language condition, but all spectral detail was replaced by noise.²³

Finally, the “silence” condition consisted of five 30-second blocks where no stimuli were presented.

Mental Imagery Paradigm

Prior to imaging, all participants were given pre-recorded spoken instructions about how to perform the 2 mental imagery tasks (motor imagery and spatial navigation), which have been described in detail previously.²¹ For the motor imagery task,

participants were instructed to imagine playing a vigorous game of tennis. For the spatial navigation task, individuals were instructed to imagine moving from room to room in their home and visualize everything they saw. Both paradigms were 5 and one-half minutes in length and had an interleaved block design

Table. Demographic Data of the Patient Population

Study ID	Age	Sex	Etiology	Time of scan post-ictus	GCS at scan (E, M, V)	GOS	Sound	Speech	Language	MI	SN	Sedation
1	67	F	Hepatic failure	9 days	8 (3, 4, 1 T)	4	+	+	-	-	-	Hydromorphone 0.5 mg/h infusion
2	66	M	Intracerebral hemorrhage with bi-hemispheric infarcts involving frontal and temporal lobe	23 days	5 (1, 3, 1 T)	2	-	-	-	-	-	None
3	66	F	Cardiac arrest	11 days	8 (3, 4, 1 T)	5	+	+	+	-	-	None
4	28	M	Status epilepticus	3 mo	6 (4, 1, 1 T)	3	+	+	-	-	-	Midazolam 0.5 mg/h infusion
5	42	M	Stroke with bilateral deep white matter watershed infarcts	22 days	9 (4, 4, 1 T)	2	+	+	-	-	-	None
6	32	M	Status Epilepticus	5 mo	6 (4, 1, 1 T)	2	-	-	-	-	-	None
7	59	F	Brain abscess	13 days	9 (4, 4, 1 T)	3	+	+	+	-	-	None
8	30	M	Intracerebral hemorrhage involving left occipital lobe	8 days	7 (2, 4, 1 T)	2	+	+	+	-	-	Fentanyl 50 mcg/h infusion
9	62	M	Cardiac arrest	4 days	3 (1, 1, 1 T)	1	+	-	-	-	-	None
10	20	M	TBI + cardiac arrest	21 mo	8 (4, 3, 1 T)	2	+	-	-	-	-	None
11	30	M	Infection (secondary to brainstem tumor)	3 days	6 (4, 1, 1 T)	3	+	+	-	-	-	None
12	36	M	Hepatic failure	6 days	6 (1, 4, 1 T)	1	+	+	+	-	-	Fentanyl 25 mg bolus
13	67	F	HSV encephalitis	22 days	6 (1, 4, 1 T)	4	+	-	-	-	-	None
14	38	F	Intraventricular hemorrhage with deep white matter infarcts	32 days	7 (2, 4, 1 T)	3	+	+	-	-	-	None
15	55	M	Cardiac arrest	4 days	3 (1, 1, 1 T)	5	+	+	-	-	-	Propofol 3 mg/kg/h infusion
16	34	M	Diffuse axonal injury	26 days	8 (4, 3, 1 T)	4	+	+	-	-	-	None
17	25	M	Diffuse axonal injury	11 days	4 (2, 1, 1 T)	4	+	+	+	?	+	None

GCS = Glasgow Coma Scale; GOS = Glasgow Outcome Scale; HSV = herpes simplex virus; MI = motor imagery; SN = spatial navigation; TBI = traumatic brain injury.

of 30 seconds of mental imagery with alternating rest periods (5 blocks of imagery and 6 blocks of rest).

fMRI Analysis. Image preprocessing and statistical analyses were conducted using Statistical Parametric Mapping (SPM8, www.fil.ion.ucl.ac.uk/spm). Functional images were manually AC-PC re-oriented, re-aligned to help correct for motion, co-registered to the structural images, normalized to MNI space using the echo planar imaging template provided in SPM8, and smoothed using an

8 mm FWHM Gaussian kernel. Single-subject fixed effect analysis was used for each participant. Based on the general linear model (GLM), regressors for each condition in the auditory and mental imagery paradigms were created by convolving boxcar functions with the canonical hemodynamic response function. Movement parameters were included as covariates in all paradigms. Translation and rotation parameters did not exceed an average of 2 mm or 2 degrees for participants and did not affect coregistration for any participant.

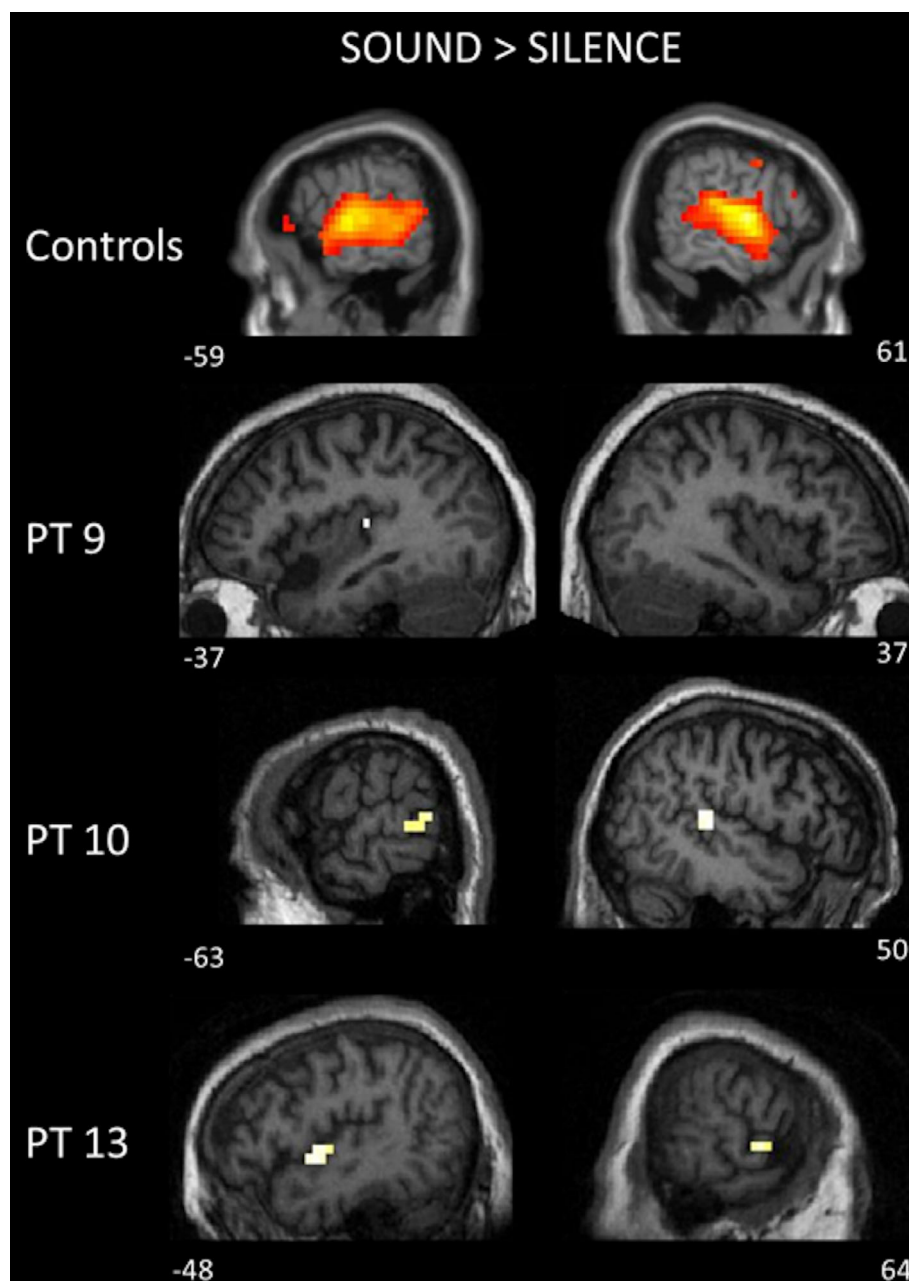


Figure 1: Three patients had significant auditory responses to only the sound perception contrast. Individual patient results are thresholded at $p < 0.001$, uncorrected, masked inclusively by the group analysis of healthy control participants. Healthy control group results are displayed at $p < 0.05$ FDR-corrected. Activations are shown on slices where the peak activation was observed. FDR = false discovery rate.

Following a previously developed method,^{17,18} sound perception was assessed by comparing the hemodynamic responses of all 3 auditory stimuli conditions (SCN, complex language, and pseudoword sentences) to the silent baseline condition. Then, to identify areas specifically related to speech processing, both speech conditions (complex language and pseudoword sentences) were contrasted with the SCN condition. Finally, to identify the fMRI responses specifically related to language comprehension, the complex language condition was contrasted with the pseudoword condition.

Functional activation in the patients was assessed by examining specific regions of interest (ROI) that were derived from the group of healthy controls. For the sound and speech perception contrasts, these ROIs were generated from the healthy control group analysis using a threshold of $p < 0.05$, false discovery rate (FDR)-corrected. Given that the patients were to be analyzed individually, a peak voxelwise threshold of $p < 0.001$, uncorrected was chosen to examine these ROIs in each individual. For the language comprehension task, ROIs were generated using the healthy control group from the contrast between the complex language condition and the pseudoword sentences condition using a threshold of $p < 0.01$, uncorrected. This previously developed approach was used to accommodate the fact that the complex language condition and the pseudoword sentence condition are very closely matched and typically reveal only modest statistical differences, even in healthy controls.¹⁸ For the tennis imagery task, an ROI was constructed based on responses in healthy controls around the supplementary motor area (SMA). For the spatial navigation task, the occipital parietal junction (OPJ) was chosen as the main ROI because this region produces the most reliable and consistent response in healthy controls.¹⁵ These ROIs were defined using a within-group analysis (one sample t -test) from the healthy control group using a cluster-defining voxelwise threshold of $p < 0.001$ (uncorrected), followed by a whole-brain FDR correction for significance using cluster extent, $p < 0.05$.

Results

Group 1: Patients Who Had No Auditory Response

In 2 patients (Patients 2 and 6; see the Table), no significant fMRI responses were observed within any of the imaging tasks.

Group 2: Patients Who Responded to Sound Stimuli Only

Three patients (Patients 9, 10, and 13) showed evidence of fMRI activity in the sound perception contrast only

(Fig 1). Two of these patients (Patients 10 and 13) had typical bilateral activation, whereas one patient (Patient 9) had one small cluster of activity within the left temporal lobe.

Group 3: Patients Who Responded to Sound and Speech Stimuli Only

Seven patients (Patients 1, 4, 5, 11, 14, 15, and 16; see the Table) showed evidence of fMRI activity in the sound *and* speech perception contrasts (Fig 2). Two of the 7 patients (Patients 11 and 16) showed appropriate bilateral activation to both the sound and speech contrasts, whereas in the remainder of patients, responses that were at least partially similar to controls were observed.

Group 4: Patients Who Responded to Sound, Speech and Language Stimuli

In 5 patients (Patients 3, 7, 8, 12, and 17; see the Table), activation was detected for all 3 levels of auditory processing (Fig 3). Two of these patients (Patients 3 and 7) showed responses similar to those seen in healthy controls, whereas in the remainder, responses that were at least partially similar to controls were observed in either one or the other conditions.

Group 5: A Single Patient Who Demonstrated Covert Command Following

Only one patient displayed any evidence of covert command following. In this individual (Patient 17), the spatial navigation task elicited significant activity in OPJ (Fig 4A), that was within the bounds of normal variability found in controls (Fig 4B).

In healthy volunteers, motor imagery produces significant activation in the supplementary motor area (Fig 4C). When Patient 17 was instructed to perform the motor imagery task, no significant activity was observed within this area; however, significant activity was observed in the adjacent left medial superior frontal gyrus (see Figures 4C and 4D).

Relationship Between fMRI Findings, Outcome and Diagnosis

A Spearman's rank order correlation coefficient was calculated to assess the relationship between the patients' fMRI results and their best Glasgow Outcome Score (GOS) within 6 months post-injury, where 1 = death and 5 = good recovery. Accordingly, the patients were grouped into 5 levels (1 = patients showing no auditory responses; 2 = patients showing a response to sound only; 3 = patients showing responses to sound and speech only; 4 = patients showing responses to sound, speech, and comprehension; and 5 = the patient who showed command following). Patient 12 (non-traumatic brain injury

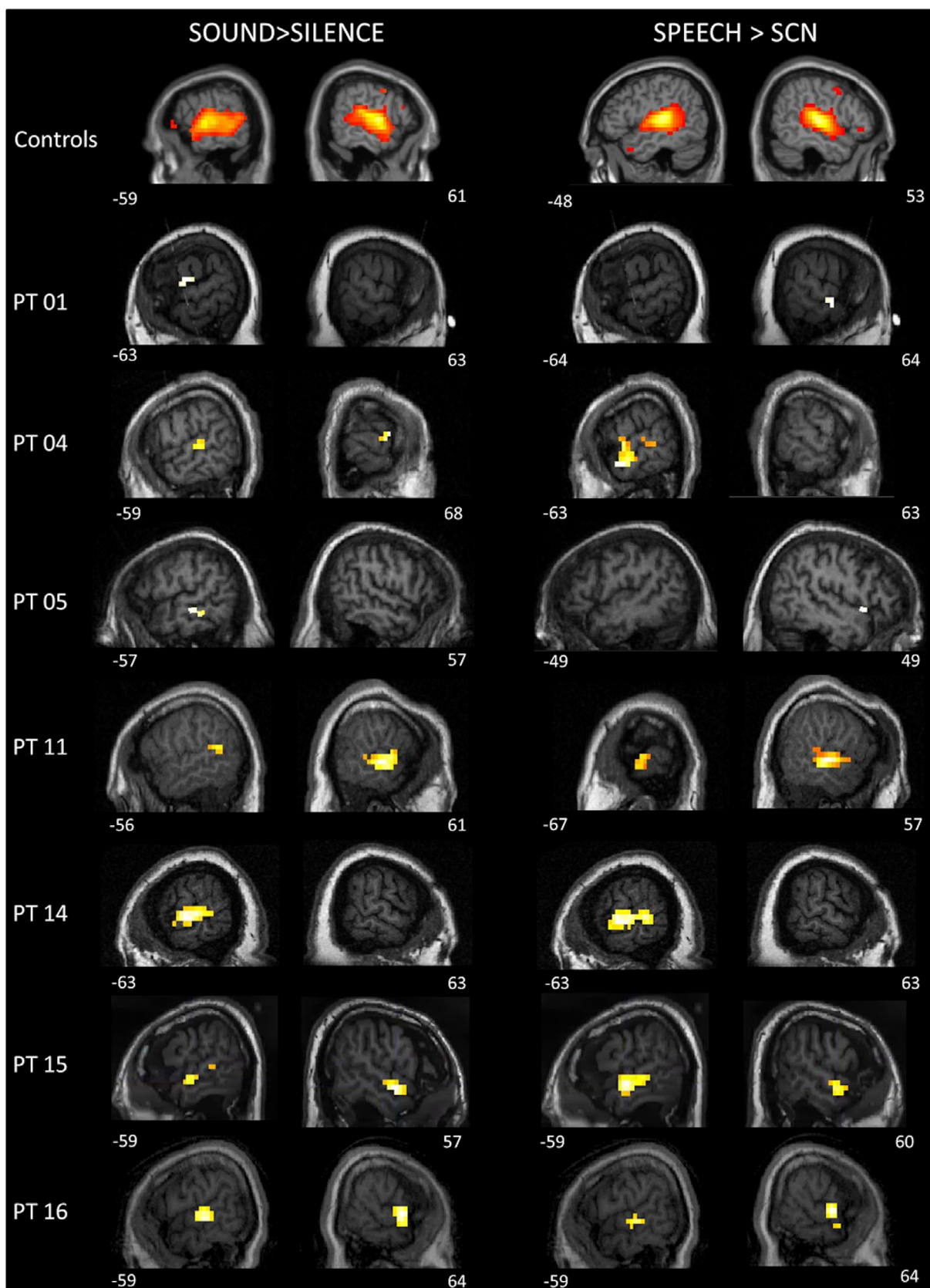


Figure 2: Seven patients had significant auditory responses to both the sound perception and speech perception contrasts. Individual patient results are thresholded at $p < 0.001$, uncorrected, masked inclusively by the group analysis of healthy control participants. Healthy control group results are displayed at $p < 0.05$ FDR-corrected. Activations are shown on slices where the peak activation was observed. FDR = false discovery rate.

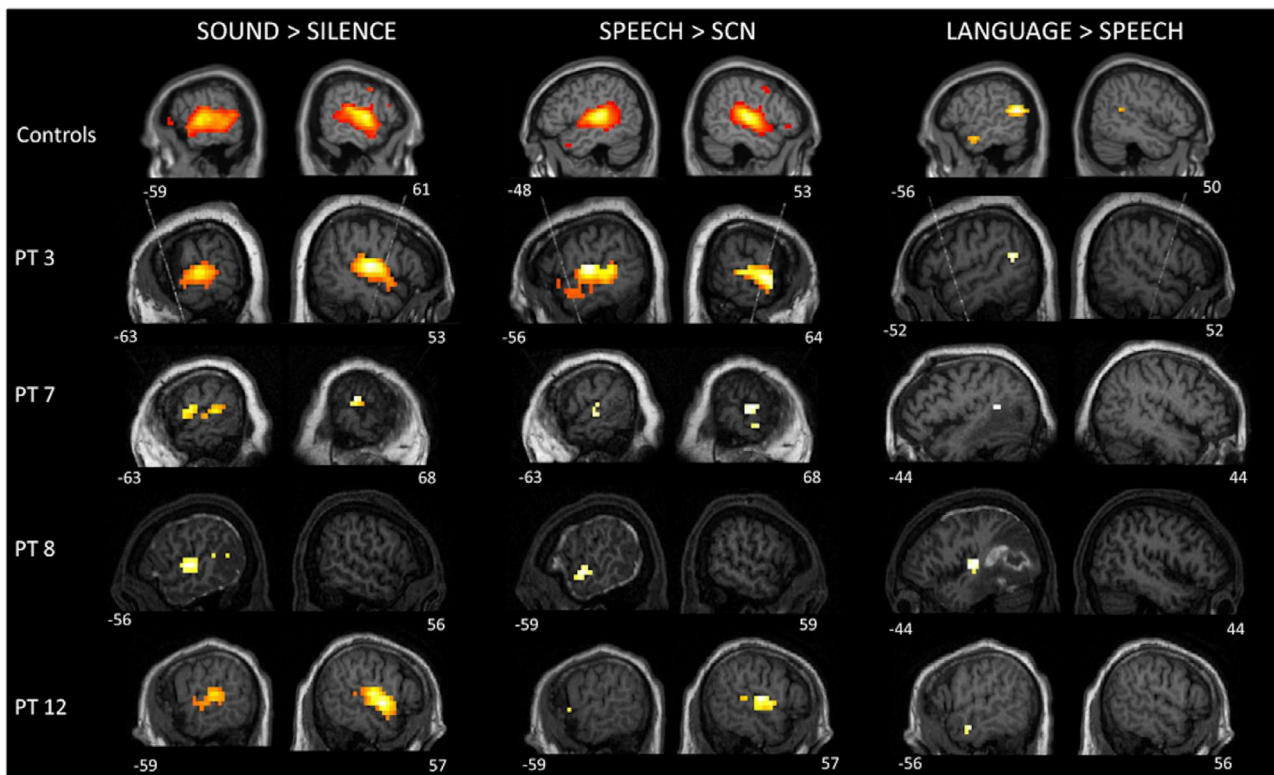


Figure 3: Patients with significant auditory responses to 3 levels of auditory processing, including sound perception, speech perception, and language comprehension contrasts. Individual patient results are thresholded at $p < 0.001$, uncorrected, masked inclusively by the group analysis of healthy control participants. Healthy control group results are displayed at $p < 0.05$ FDR-corrected. Activations are shown on slices where the peak activation was observed. FDR = false discovery rate.

[TBI]) developed sepsis shortly following imaging and life-sustaining therapy was withdrawn due to multi-organ failure. Therefore, this patient was excluded from this analysis, as his best neurological outcome could not be known. A significant positive relationship was observed between the level of fMRI response and the patients' best GOS score ($r_s = 0.472$, $p = 0.032$). There was no significant relationship between the patients' fMRI response and their extent of impaired consciousness (GCS) at the time of imaging ($r_s = 0.300$, $p = 0.259$).

Discussion

A hierarchical fMRI approach was used to assess sound perception, speech perception, language comprehension, and covert command following in 17 brain-injured patients admitted to the ICU. The passive auditory task was designed to assess the extent of auditory processing in a systematic way; that is, to discriminate between lower-level perceptual processing of sounds, mid-level perceptual processing of speech, and higher-order language comprehension.

Fifteen patients produced significant neural activation within the primary auditory cortex similar to healthy

volunteers, suggesting intact sound perception. The mid-level speech perception contrast elicited significant activation in 12 patients within bilateral superior and middle temporal gyri, suggesting that the majority of patients also retained the ability to *perceive* speech. Whereas encouraging with respect to preserved brain function, these findings do not necessarily mean that these patients are having any conscious experience associated with perceiving these stimuli. For example, the fMRI signatures associated with both sound perception and speech perception persist when healthy participants are heavily sedated and, therefore, demonstrably “unconscious.”^{22,24}

On the other hand, those same sedation studies have shown that the fMRI responses associated with the higher-level semantic processes that support language comprehension are abolished, even under light sedation in healthy participants, suggesting that they depend, at least in part, on awareness.²⁴ It is perhaps surprising then, that 5 of 17 of the patients included in this study elicited significant neural responses in the highest-level language contrast, suggesting a level of speech comprehension that is similar to that seen in healthy volunteers. Thus, we conclude that some aspects of high-level language processing (“speech comprehension”) may be present in some

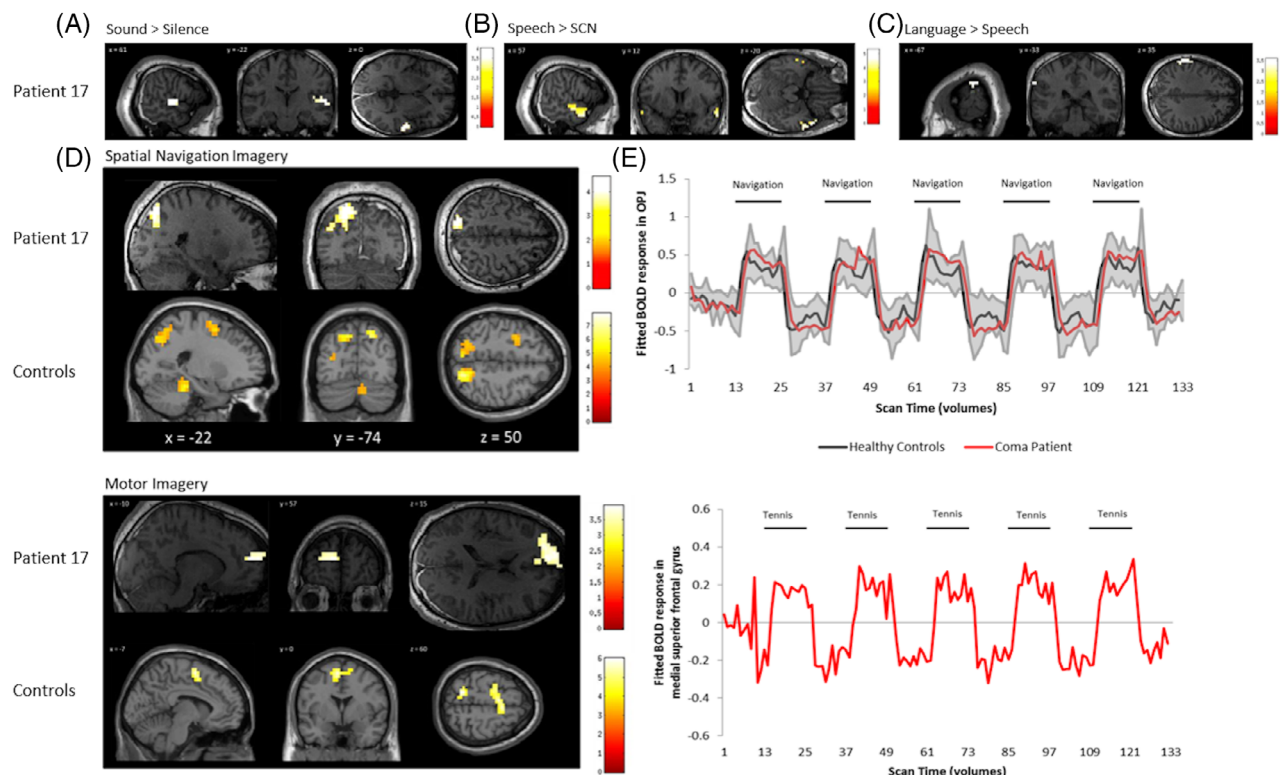


Figure 4: Results of functional imaging from Patient 17. (A) Significant activation to the sound perception. (B) significant activation to the speech perception condition. (C) Significant activation to the language comprehension. For sound and speech perception, the patient's results are thresholded at $p < 0.001$, uncorrected, masked inclusively by the group analysis of healthy control participants thresholded at $p < 0.05$ FDR corrected. For language comprehension, whole-brain results are displayed on slices where peak was observed at an uncorrected threshold of $p < 0.001$. (D) Spatial navigation findings using a whole-brain analysis revealed significant activation in the occipito-parietal junction with results displayed at a peak voxelwise threshold $p < 0.001$, uncorrected, followed by whole-brain FDR-corrected for significance using cluster extent, $p < 0.05$. (E) Plot of the BOLD timecourse within the peak voxel in the occipito-parietal junction for the spatial navigation task as a function of the scan duration for comatose patient 17 (red) and healthy control participants (mean timecourse in black and SD shaded in gray). (F) Tennis imagery using a whole-brain analysis revealed significant activation in the left medial superior frontal gyrus with results displayed at a peak voxelwise threshold $p < 0.001$, uncorrected, followed by whole-brain FDR-corrected for significance using cluster extent, $p < 0.05$. (G) BOLD signal change obtained from Patient 17 in the peak voxel of the medial superior frontal gyrus during the motor imagery task. All results are displayed on the patient's normalized T1 image. FDR = false discovery rate.

patients at the earliest stages of a brain injury, emulating the findings reported previously in patients diagnosed as VS or MCS.^{18,23} These results also complement a recent study that showed speech comprehension can be detected in acute patients using an electroencephalogram (EEG).²⁵ However, without any behavioral response, any conclusion regarding awareness in this population has to be considered speculative.²⁶ To address this issue, we also used 2 imagery tasks that can detect unequivocally whether awareness is intact.¹⁴ One patient showed evidence that he could willfully modulate his brain activity when instructed to do so, despite the lack of behavioral awareness at the bedside. Thus, when prompted to imagine moving through his home, he generated consistent and repeatable fMRI responses, that were indistinguishable from those observed in healthy controls. This reflects an intentional response that does not occur in the absence of

conscious awareness.¹⁴ In the same patient, significant fMRI responses were observed to sound perception, speech perception, and language comprehension, providing good evidence that the lower-level cognitive processes required to support high-level cognition also remained intact.

It is notable that of the 17 patients studied here, only one showed any evidence of consistent command following. This suggests that the incidence of covert awareness in an acute disorder of consciousness, as detected by functional neuroimaging, may be lower than the figure that has been reported for chronic disorders of consciousness (approximately 15–20%).^{16,26} This could indicate that covert awareness is rarer in acute disorders of consciousness or, alternatively, that functional neuroimaging may have a lower sensitivity for detecting awareness in the acute stage. We favor the latter of these 2 possibilities, in

part because 5 of 17 of these patients showed evidence of higher-order language comprehension during the hierarchical auditory task. Perhaps awareness was preserved in some of these 5 patients, but given the high cognitive demands of these mental imagery tasks, they may have been unable to elicit a response that could be detected with the fMRI scanner. Furthermore, a recent EEG study demonstrated that 15% of patients with brain injury in the ICU who were unable to overtly respond to motor commands had detectable neural activity when given more simplistic instructions, suggesting that the incidence rates of covert awareness in acute and chronic disorders of consciousness may be similar.²⁷

The results of this study showed that the level of fMRI responsivity was related to the highest level of recovery within the first 6 months. That is to say, the higher the level of residual cognitive functioning (as indexed by fMRI responses), the more likely the patient was to make some functional recovery. The use of fMRI as a prognostic tool in this context also finds support from other studies that have shown that activation in higher-order associative cortices is predictive of recovery in *chronic* vegetative and minimally conscious states.¹⁸ Although incremental gains can occur in chronic conditions, the largest leaps in the recovery of consciousness are likely to occur in the first few weeks following an injury. If functional neuroimaging can aid in prognostication, therefore, it is likely to be most useful in acute conditions, such as coma.

Several previous studies have examined whether fMRI has a prognostic role to play in acute disorders of consciousness. In most cases, these studies used passive tasks to assess primary sensory processing or task-free resting state conditions.^{6,7,10,28} Nevertheless, each of these studies suggested a relationship between the fMRI findings and prognosis, in line with the results of the current study. One recent study used *active* fMRI tasks, including a command-following paradigm, to assess a group of patients with TBI in the ICU.¹¹ The results showed that fMRI can be used to identify covert consciousness in some acute patients, which we have again confirmed here. However, in that study, no clear association was detected between functional outcome and the neuroimaging findings, whereas a significant correlation was observed in the current investigation. There are a number of possible reasons for this discrepancy. In particular, that study used each patient's GOS score at 6 months as their measure of functional outcome, whereas in the current study, the best GOS score that was reached *within* the first 6 months was used. This decision was made because, in this study, 7 of 17 (41%) patients died (due to withdrawal of life-sustaining treatment), and so their GOS score at 6 months would not have accurately captured any recovery of

consciousness that had occurred prior to that point. In contrast, in the study by Edlow and colleagues, far fewer patients died (12.5%), meaning that the 6-month GOS score was likely to be more representative of their actual level of recovery.

There are unique challenges in the use of fMRI as a clinical tool in the ICU. First, fMRI may be impractical in certain cases. Severe TBIs that result in deformations of the brain may prevent the “normalization” of the acquired images to a standard healthy brain template.² Second, transporting critically ill patients to the MRI scanner increases the risk of adverse events.²⁹ Third, relating fMRI findings to outcome is extremely challenging in critically ill patients because a large proportion will have life support therapies withdrawn, making it impossible to determine what would be the true mortality rate if these patients had been allowed to live.³⁰ This makes it very difficult to determine the sensitivity and specificity of novel prognostic tests (such as fMRI), because there is no “absolute truth” against which the novel method can be assessed. In our study, for 8 patients who died prior to the 6-month follow-up, their best outcome score was extracted from a chart review; although this methodological approach could pose an inherent risk of bias based on its retrospective nature, it is not clear how such a bias could have yielded the overall pattern of results observed. Finally, negative functional neuroimaging findings in patients should never be used as evidence for impaired cognitive function or lack of awareness.^{31,32} False-negative findings in functional neuroimaging studies are common, even in healthy volunteers, and they present particular difficulties in this patient population. Although not used in this study, future studies that examine consciousness in patients within the ICU should consider using the Coma Recovery Scale-Revised (CRS-R) over the more traditional GCS as it has a greater sensitivity for detecting behavioral aspects of conscious awareness at the bedside.³³ Additionally, within our study we tried to image patients following cessation of sedation, where possible. Five patients required sedation medication during imaging, with patient 15 receiving a large infusion of medication which may have contributed to the lack of activation in higher-order cognitive tasks. Of course, in all cases, residual sedation would only be expected to increase the number of false negative results rather than contribute to any of the fMRI activity observed in “neurally responsive” patients. Future research should consider postponing imaging of patients receiving high doses of sedation which may impact the neural activation observed. Despite the fact that the study only involved a small number of participants (from both acute and chronic patient groups), it has indicated promising results for future clinical trials evaluating the use of

fMRI in critical illness. These investigations should include large, longitudinal, and multicenter studies to reach definitive conclusions about optimal, efficient, and reliable testing. Importantly, longitudinal studies that examine changes in cortical responses of patients with brain injuries in repeated assessments should correlate those findings to functional recovery in the hope that they will delineate early patterns of brain activity that may predict the subsequent extent of severity of disability in survivors.

In summary, these results represent that fMRI can be both diagnostically and prognostically informative in acute severe brain injury. As such, they will have a significant and direct impact on the assessment and clinical care of patients in the ICU, inform medical ethics and legal discussions, and drive efforts to develop interventions to facilitate recovery and quality of life after serious brain injury.

Acknowledgments

The authors gratefully acknowledge the hard work and dedication of the MRI technologists and ICU staff at London Health Sciences Centre. This work was supported by the Canada Excellence Research Chairs Program (#215063). The funder had no role in the design of the present study.

Author Contributions

L.N. and A.M.O. contributed to the design of the study. All authors contributed to the acquisition, analysis, and interpretation of data. L.N., K.K., and A.M.O. contributed to drafting a significant portion of the manuscript or figures.

Potential Conflicts of Interests

The authors declare no competing interests.

References

- Kamps MJA, Horn J, Oddo M, et al. Prognostication of neurologic outcome in cardiac arrest patients after mild therapeutic hypothermia: a meta-analysis of the current literature. *Intensive Care Med* 2013;39:1671–1682.
- Weijer C, Bruni T, Gofton T, et al. Ethical considerations in functional magnetic resonance imaging research in acutely comatose patients. *Brain* 2016;139:292–299.
- Li L, Kang X-G, Qi S, et al. Brain response to thermal stimulation predicts outcome of patients with chronic disorders of consciousness. *Clinical neurophysiology: official journal of the International Federation of Clinical Neurophysiology* 2014;126:1539–1547.
- Di H, Boly M, Weng X, et al. Neuroimaging activation studies in the vegetative state: predictors of recovery? *Clinical medicine. J R Coll Physicians Lond* 2008;8:502–507.
- Wang F, Di H, Hu X, et al. Cerebral response to subject's own name showed high prognostic value in traumatic vegetative state. *BMC Med* 2015;13:1–13.
- Gofton TE, Chouinard PA, Young GB, et al. Functional MRI study of the primary somatosensory cortex in comatose survivors of cardiac arrest. *Exp Neurol* 2009;217:320–327.
- Norton L, Hutchison RM, Young GB, et al. Disruptions of functional connectivity in the default mode network of comatose patients. *Neurology* 2012;78:175–181.
- Koenig MA, Holt JL, Ernst T, et al. MRI default mode network connectivity is associated with functional outcome after cardiopulmonary arrest. *Neurocrit Care* 2014;20:348–357.
- Sair HI, Hannawi Y, Li S, et al. Early functional connectome integrity and 1-year recovery in comatose survivors of cardiac arrest. *Radiology* 2018;287:247–255.
- Wagner F, Hänggi M, Weck A, et al. Outcome prediction with resting-state functional connectivity after cardiac arrest. *Sci Rep* 2020;10:11695.
- Edlow BL, Chatelle C, Spencer CA, et al. Early detection of consciousness in patients with acute severe traumatic brain injury. *Brain* 2017;140:2399–2414.
- Owen AM, Coleman MR. Detecting awareness in the vegetative state. *Ann N Y Acad Sci* 2008;1129:130–138.
- Schnakers C, Vanhaudenhuyse A, Giacino J, et al. Diagnostic accuracy of the vegetative and minimally conscious state: clinical consensus versus standardized neurobehavioral assessment. *BMC Neurol* 2009;9:35.
- Owen AM, Coleman MR, Boly M, et al. Detecting awareness in the vegetative state. *Science* 2006;313:1402.
- Boly M, Coleman MR, Davis MH, et al. When thoughts become action: an fMRI paradigm to study volitional brain activity in non-communicative brain injured patients. *Neuroimage* 2007;36:979–992.
- Kondziella D, Friberg CK, Frokjaer VG, et al. Preserved consciousness in vegetative and minimal conscious states: systematic review and meta-analysis. *J Neurol Neurosurg Psychiatry* 2016;87:485–492.
- Coleman MR, Rodd JM, Davis MH, et al. Do vegetative patients retain aspects of language comprehension? Evidence from fMR Brain 2007;130:2494–2507.
- Coleman MR, Davis MH, Rodd JM, et al. Towards the routine use of brain imaging to aid the clinical diagnosis of disorders of consciousness. *Brain* 2009;132:2541–2552.
- Peelle JE, Troiani V, Wingfield A, Grossman M. Neural processing during older adults' comprehension of spoken sentences: age differences in resource allocation and connectivity. *Cereb Cortex* 2010;20:773–782.
- Schroeder MR. Reference signal for signal quality studies. *J Acoust Soc Am* 1968;44:1735–1736.
- Fernández-Espejo D, Norton L, Owen AM. The clinical utility of fMRI for identifying covert awareness in the vegetative state: a comparison of sensitivity between 3T and 1.5T. *PLoS one* 2014;9:e95082.
- Adapa RM, Davis MH, Stamatakis EA, et al. Neural correlates of successful semantic processing during propofol sedation. *Hum Brain Mapp* 2014;35:2935–2949.
- Owen A, Coleman M, Menon D, et al. Residual auditory function in persistent vegetative state: a combined pet and fmri study. *Neuropsychol Rehabil* 2005;15:290–306.
- Davis MH, Coleman MR, Absalom AR, et al. Dissociating speech perception and comprehension at reduced levels of awareness. *Proc Natl Acad Sci U S A* 2007;104:16032–16037.
- Sokoliuk R, Degano G, Banellis L, et al. Covert speech comprehension predicts recovery from acute unresponsive states. *Ann Neurol* 2021;89:646–656.

26. Monti MM, Vanhaudenhuyse A, Coleman MR, et al. Willful modulation of brain activity in disorders of consciousness. *N Eng J Med* 2010;362:579–589.
27. Claassen J, Doyle K, Matory A, et al. Detection of brain activation in unresponsive patients with acute brain injury. *N Engl J Med* 2019; 380:2497–2505.
28. Pugin D, Hofmeister J, Gasche Y, et al. Resting-state brain activity for early prediction outcome in postanoxic patients in a coma with indeterminate clinical prognosis. *Am J Neuroradiol* 2020;41:1022–1030.
29. Fanara B, Manzon C, Barbot O, et al. Recommendations for the intra-hospital transport of critically ill patients. *Crit Care* 2010;14:R87.
30. Wilkinson D. The self-fulfilling prophecy in intensive care. *Theor Med Bioeth* 2009;30:401–410.
31. Owen AM, Coleman MR. Functional MRI in disorders of consciousness: advantages and limitations. *Curr Opin Neurol* 2007;20: 632–637.
32. Owen AM, Coleman MR, Boly M, et al. Using functional magnetic resonance imaging to detect covert awareness in the vegetative state. *Arch Neurol* 2007;64:1098–1102.
33. Edlow BL, Fins JJ. Assessment of covert consciousness in the intensive care unit: clinical and ethical considerations [internet]. *J Head Trauma Rehabil* 2018;33:424–434. Available from: <https://journals.lww.com/00001199-201811000-00008>.